

Palatally impacted mesiodens - A case report

Chaturvedi R*, Kumar A**, Kumar V***

*Department of Pedodontics & Preventive Dentistry, Kalka Dental College, Meerut

**Department of Oral and Maxillofacial Surgery, Kalka Dental College, Meerut

***Department of Prosthodontics and Implantology, Kalka Dental College, Meerut

ARTICLE INFO

Keywords:

Inverted impacted, Mesiodens, Supernumerary teeth

Corresponding Author:

Dr. Renu Chaturvedi
A-13, Vaishali Colony, Garh Road,
Meerut-250003, Uttar-Pradesh.
Contact: +919837100900
Email: dagur_ashish@yahoo.com

ABSTRACT

Mesiodens is a type of supernumerary tooth located between maxillary central incisors. It is usually a small tooth with a cone- or - peg shaped crown and a short root. It may be single or paired, erupted or impacted and at times even inverted. The presence of a mesiodens should be suspected if there is delayed eruption of the permanent incisors or if the central incisors are displaced, malposed or exhibit spacing. Associated complications include crowding, displacement, root resorption, diastema, or dentigerous cyst formation. It is diagnosed through clinical and radiological examination using maxillary anterior periapical and panoramic radiography. In addition, maxillary occlusal radiography is highly recommended for all children with disturbance in maxilla. An 8 year-old male patient was brought to the dental department for routine checkup. Intraoral examination revealed irregular upper front teeth. Radiological evaluation revealed impacted mesiodens between maxillary central incisors. This case report describes an incidental finding of impacted mesiodens.

Introduction

The term "mesiodens" was coined by Bolk in 1917.[1] Mesiodens refers to a supernumerary tooth located between maxillary central incisors.[2] Mesiodens is a type of supernumerary tooth that appears most frequently, between 47% and 67% of cases, with a prevalence of 0.15-1.9% in the general population.[3,4] Most of the mesiodentes are impacted.[5]

Asymptomatic unerupted mesiodens may be discovered during a radiological examination of the premaxillary area. Mesiodens may give rise to a variety of complications such as impaction, delayed eruption and ectopic eruption of adjacent teeth, crowding, diastema, axial rotation, radicular resorption of adjacent teeth, and dentigerous cyst.[6,7]

It may be single or paired, erupted or impacted and at times even inverted. The presence of a mesiodens should be suspected if there is delayed eruption of the permanent incisors or if the central incisors are displaced, malposed or exhibit spacing.[8-10]

Mesiodens can be classified on the basis of their occurrence in the permanent dentition (rudimentary mesiodentes) or primary dentition (supplementary mesiodentes) The classification of supernumerary teeth is also based on their morphology together with their location in the dental arches.[11] According to the shape and size, two subclasses are considered in the classification of mesiodens; namely, eumorphic and dysmorphic. The eumorphic subclass is usually similar to a normal-sized central incisor, whereas the dysmorphic teeth have different shapes and sizes and are categorized into conical, tuberculate, supplemental and odontomes. Therefore, supernumerary teeth might vary from a normal tooth to a dysmorphic mass.[12]

To minimize these complications, early diagnosis, and appropriate management of the supernumerary teeth is essential for a more favorable prognosis in order to prevent aesthetic and occlusal problems. This article describes a case of palatally impacted mesiodens, placed high in the palate.

Case Report

An eight year old boy reported to our clinic with chief complaint of dirty teeth. The Patient gave no significant medical or dental history. On intraoral examination, patient had irregularly placed maxillary central incisors with proclined right maxillary central incisor and retroclined left maxillary central incisor (Figure 1).

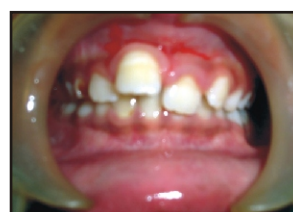

Figure 1 Irregularly placed maxillary central incisors with proclined right maxillary central incisor and retroclined left maxillary central incisor




Figure 2. Occlusal radiograph showing impacted mesiodens tooth

Various radiographic investigations like OPG, occlusal and IOPA revealed impacted mesiodens tooth (Figure 2). Hematological investigations were performed which showed no positive findings. Surgical removal of the impacted mesiodens (Figure 3, 4) was done and sutures were placed (Figure 5, 6).

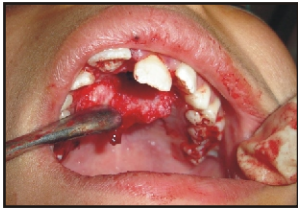

Figure 3. Intraoperative photograph during mesiodens removal

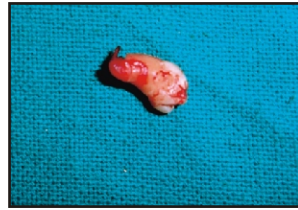

Figure 4. Surgically removed mesiodens

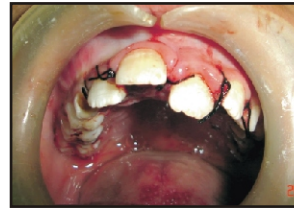

Fig.5. Postoperative photograph with sutures placed

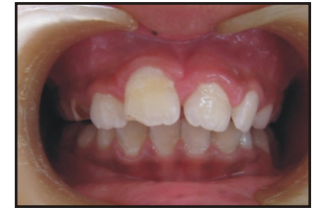

Fig.6. Postoperative photograph after 2 weeks

Discussion

Supernumerary teeth/ hyperdontia are the teeth that exceed the normal dental formula, independent of their location and form. A mesiodens is a supernumerary tooth located in the maxillary central incisor region. A few epidemiological studies have been conducted and there is considerable variation between their findings. The reported prevalence in general population ranges between 0.15% and 1.9% and it is reported to be more common in males rather than females.[12]

The occurrence of mesiodens in primary dentition is quite rare despite the fact that in permanent dentition it has even been considered as the most common dental abnormality.[13] Most cases of mesiodens are discovered during the first decade as maxillary central incisors are erupting and radiographic examinations are performed as an aid to screening for congenitally missing teeth, supernumerary teeth, cysts and tumors when delayed eruption or malposition of the maxillary central incisors are seen.[9]

Mesiodens can occur individually or as multiples and often do not erupt. They are generally peg shaped and are usually located palatally between the maxillary central incisors, tending to displace the erupting permanent central incisors.

The etiology of mesiodens remains unclear; The literature reports three theories regarding the etiopathogenesis of mesiodens but the subject remains controversial.[8,10] The observation that supernumeraries are more common in family members suggests heredity as an etiologic factor; however, it does not follow a simple Mendelian pattern.[14] Supernumerary teeth may occur in isolation or as part of a syndrome such as cleidocranial dysplasia, Gardner's syndrome, cleft lip & palate etc.[15] It has been suggested that environmental factors might have influence on genetic susceptibility. The possibility of genetic transmission via an autosomal dominant trait with lack of penetration has been observed and an X-linked inheritance has been documented which can explain sex dominance in this anomaly.[16]

Genetics is also thought to contribute to the development of mesiodens. It was originally postulated that the mesiodens represented a phylogenetic relic of the extinct ancestors who had three central incisors. This is known as phylogenetic theory reversion (atavism) has now been discarded by the embryologists.

It has also been mentioned that environmental factors might play a role in the occurrence of mesiodens as well as splitting of the tooth bud or the dichotomy theory. According to the dichotomy theory, Taylor argued that splitting of the tooth bud into two equal or unequal sections may either form two equal sized teeth or one normal and one dysmorphic tooth. [13]

The hyperactivity theory, which is the restricted increase in the activity of dental lamina, may be considered as the most acceptable, without radiographic evaluation, etiologic factor in the development of mesiodens.

First the 'field model', proposes that the factors responsible for tooth shape reside within the ectomesenchyme, in distinct but graded fields for each tooth family. Thus, a tooth bud which is forming at a given location develops according to its position within the field.[17]

The 'clone model' states that the ectomesenchyme, as it migrates into the jaws, becomes segregated into three clones: incisor, canine and molar. It may be that both models can be combined for temporal factors may play a role. Either way, once an accessory tooth germ forms in the vicinity of the incisors class of teeth its epithelium is equipped with signaling molecules. The signaling molecule, fibroblast growth factor, is expressed widely within the first arch epithelium. Depending upon the interplay of these factors, the shape of the mesiodens becomes evident at the bell stage.

It is discussed in the literature that the sooner the diagnosis the better the prognosis. The diagnosis may be possible as early as in the age of 2.[18] In primary dentition, mesiodens often have normal shape and erupt normally and this is the reason why these teeth are often overlooked. The other possible reason for the less frequent reporting of primary mesiodens might be the difficulty in its detection by the caregiver. It is common that anterior primary mesiodens erupts and exfoliates normally before detection and could be mistaken with gemination or fusion anomalies.[19]

In permanent dentition, diagnosis is much easier following eruption of the permanent anterior teeth. However, in permanent dentition, detection of supernumeraries needs thorough clinical and radiographic examination. Panoramic, maxillary occlusal and periapical radiographs are recommended to assist the process of diagnosis of mesiodens. Supernumerary teeth are usually single and unerupted. If positioned in the anterior location, more problems will be caused due to altered growth and development in the area. Impaction of the permanent incisors due to the presence of mesiodens is common. These teeth usually erupt spontaneously after extraction of the mesiodens.[20,21]

Management of supernumerary teeth depends on the type and position of the tooth. Immediate removal of mesiodens is usually indicated in the following situations; inhibition or delay of eruption, displacement of the adjacent tooth, interference with orthodontic appliances, presence of pathologic condition, or spontaneous eruption of the supernumerary tooth. Munns [22] stated that the earlier the mesiodens is removed, the better the prognosis.

There are two methods for extraction of mesiodens; early extraction before root formation of the permanent incisors and late extraction after root formation of the permanent incisor.[13]

In order to promote eruption and proper alignment of adjacent teeth, it is recommended to extract mesiodens in the early mixed dentition, which may reduce the need for orthodontic treatment. A recent study of Yagüe-García et al [23] emphasized that the early removal of the supernumerary teeth in order to prevent complications is the treatment of choice.

The mesiodens is therefore a fairly common, though usually unperturbing but interesting dental anomaly that a dental practitioner chances upon. Awareness of its incidence and behavior is therefore significant as it can lead to prevention and early interception of developing malocclusion.

Conclusion

The mesiodens is therefore a fairly common, though usually unperturbing but interesting dental anomaly that a dental practitioner chances upon. Delayed, ectopic or asymmetric eruption of the central incisors should alert the clinician to the possibility of a mesiodens. Little knowledge regarding impacted mesiodens can prevent, big problems associated with developing malocclusion because of impacted mesiodens.

References

1. Luten Jr RL. The prevalence of supernumerary teeth in primary & mixed dentition. *J Dent Child* 1967;34:346-53.
2. White SC, Pharoah MJ. Oral radiology; principles and interpretation. 5th ed. St. Louis: Mosby-Year Book Inc; 2004.
3. Zhu JF, Marcushamer M, King DL, Henry RJ. Supernumerary and congenitally absent teeth: a literature review. *J Clin Pediatr Dent*. 1996;20:87-95.
4. Fernández Montenegro P, Valmaseda Castellón E, Berini Aytés L, Gay Escoda C. Retrospective study of 145 supernumerary teeth. *Med Oral Patol Oral Cir Bucal*. 2006;11:E339-E44.
5. Mukhopadhyay S. Mesiodens: a clinical and radiographic study in children. *J Indian Soc Pedod Prev Dent*. 2011;29:34-8.
6. Hyun HK, Lee SJ, Lee SH, Hahn SH, Kim JW. Clinical characteristics and complications associated with mesiodentes. *J Oral Maxillofac Surg* 2009;67:2639-43.
7. Lee DH, Lee JS, Yoon SJ, Kang BC. Three dimensional evaluation of impacted mesiodens using dental cone beam CT. *Korean J Oral Maxillofac Radiol*. 2010;40:109-14.
8. Primosch RE. Anterior supernumerary teeth - Assessment and surgical intervention in children. *Pediatr Dent* 1981;3(2):204-15.
9. Arx TV. Anterior maxillary supernumerary teeth: a clinical and radiographic study. *Aust Dent J* 1992;37:189-95.
10. Russell KA, Folwarczna MA. Mesiodens - Diagnosis and management of a common supernumerary tooth. *J Can Dent Assoc* 2003;69(6):362-6.
11. Foster TD, Taylor GS. Characteristics of supernumerary teeth in the upper central incisor region. *Dent Pract Dent Res* 1969;20(1):8-12.
12. Buggenhout GV, Bailleul-Forestier I. Mesiodens. *Eur J Med Genet* 2008;51(2):178-81.
13. Rajab LD, Hamdan MA. Supernumerary teeth: Review of Literature and a survey of 152 cases. *Int J of Pediatr Dent* 2002;12(4):244-54.
14. Jasmin JR, Jonesco-Benaiche N, Giamarchi MM. Supernumerary teeth in twins. *Oral Surg Oral Med Oral Pathol* 1993;76(2):258-9.
15. Sharma A. Familial occurrence of mesiodens- A case Report. *J Indian Soc Pedod Prev Dent* 2003;21:84-85.
16. Sedano HO, Golin RJ. Familial occurrence of mesiodens. *Oral surg Oral med Oral pathol* 1969;27(3):360-2.
17. Tencate AR. Oral histology. Development, structure and function. 6th ed. St. Louis Mosby, 2003.
18. Whittington BR, Durward CS. Survey of anomalies in primary teeth and their correlation with the permanent dentition. *N Z Dent J* 1996;92(407):4-8.
19. Humerfelt D, Hurlen B, Humerfelt S. Hyperdontia in children below four years of age: a radio graphic study. *ASDC J Dent Child* 1985;52(2):121-4.
20. Gallas MM, García A. Retention of permanent incisors by mesiodens: a family affair. *Br Dent J* 2000;188(2):63-4.
21. Fernandez-Montenegro P, Valmaseda-Castellon E, Berini-Aytes L, Gay Escoda C. Retrospective study of 145 supernumerary teeth. *Med Oral Patol Oral Cir Bucal* 2006;11(4):E339-44.
22. Munns D. Unerupted incisors. *Br J Orthod* 1981;8(1):39-42.
23. Yagüe-García J, Berini-Aytés L, Gay-Escoda C. Multiple supernumerary teeth not associated with complex syndromes: a retrospective study. *Med Oral Patol Oral Cir Bucal* 2009;14(7):E331-6.

Source of Support: Nil. Conflict of Interest: None